

## An 11-month-old boy with hematochezia

### History:

An 11-month-old boy has presented with bloody stool for 5 months. The parents report dripping of fresh blood after defecation. They deny history of mucous stool or diarrhea. His bowel movements are mostly associated with hard stools with a frequency of 3-4 times/week. Neither history of prolapse of rectal polyp, bleeding tendency, abdominal pain, nor skin rash was noted. The patient has thrived well. There is no history of allergic diseases in the family.

### Additional history:

He had been exclusively breast-fed until 4.5 months of age. After that, he has been fed with both breast milk and an infant formula. The solid food has been introduced when he was 6 months old.

### Physical examination:

A male infant, active  
Body weight 10 kg  
Vital signs: normal  
HEENT: not pale, no jaundice, no cervical lymphadenopathy  
Lungs: clear  
Heart: regular rhythm, no murmur  
Abdomen: soft, no hepatosplenomegaly, no mass  
Ext: no rash  
PR: anus: no fissure, normal sphincter tone

### Basic investigations:

**CBC** : Hb 12.2 g/dl, Hct 37%, WBC 9400/cumm, N28, L60, Mono8, Eos3, Baso1, platelet 260,000/cumm

**Stool examination** : soft, negative occult blood, WBC and RBC negative

**ESR** : 18 mm/hr

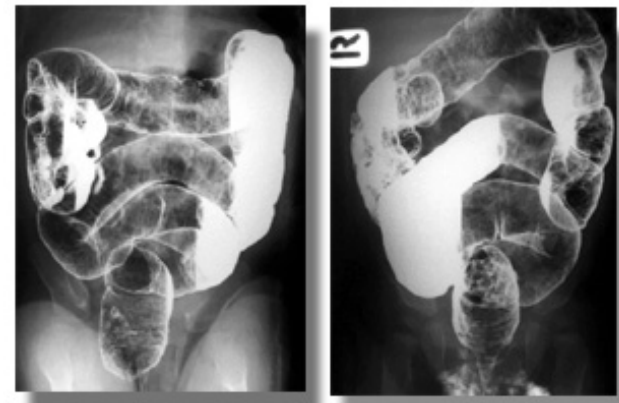### Differential diagnosis :

1. Constipation with anal fissure
2. Cow's milk protein allergy
3. Colorectal polyp
4. Colonic lymphonodular hyperplasia
5. Parasitic infection
6. Anomaly of vessel: hemangioma
7. Meckel's diverticulum

### Imaging study:

**Barium enema**: demonstrated diffuse small nodules through the colon with some center umbilication. The terminal ileum was normal.(Figure 1)

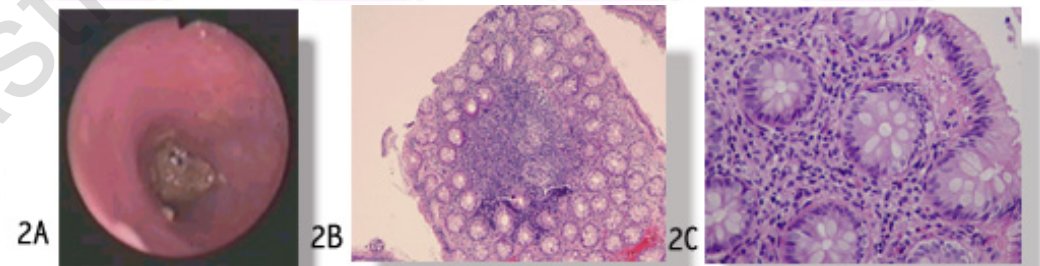
**Impression**: lymphoid nodular hyperplasia



**Figure 1:** Barium enema shows findings consistent with lymphonodular hyperplasia.

**Treatment and progression:**

The patient had initially been treated with stool softener, lactulose. His clinical picture, however, had not improved well despite the dosage of lactulose being up to 10 ml q 12hr and introduction of a protein-hydrolysate formula. Therefore, a flexible sigmoidoscopy was performed. Endoscopic findings revealed colonic mucosal nodularity with ontop erosions, in which this was confirmed in histopathologic study. There was also evidence of mucosal erosion and eosinophilic infiltration. (Figure 2)



**Figure 2:** The flexible sigmoidoscopy shows colonic mucosal nodularity (2A).

Corresponding to the pathologic study, there is lymphoid nodular hyperplasia with mucosal erosion and eosinophilic infiltration. (2B and 2C)

**Diagnosis: Lymphonodular hyperplasia (LNH)**

**Gastrointestinal lymphonodular hyperplasia**

Lymphonodular hyperplasia could be noted in both small and large bowel (43% and 57%, respectively). Most of the children present with periumbilical abdominal pain (58%), whereas bright red blood per rectum or steaky red in mucoid strand adhering to the stools comprises 32% of the cases. On contrary to abdominal pain, bleeding per rectum is a prominent clinical feature of children under 1 year of age. If colonoscopy is performed, the lesions are usually confined to the distal colon and terminal ileum, in which nodularity, friability, and ulceration can be observed. There have been studies demonstrates the possible link of food allergy and lymphonodular hyperplasia.

[PthaiGastro.org](http://PthaiGastro.org)