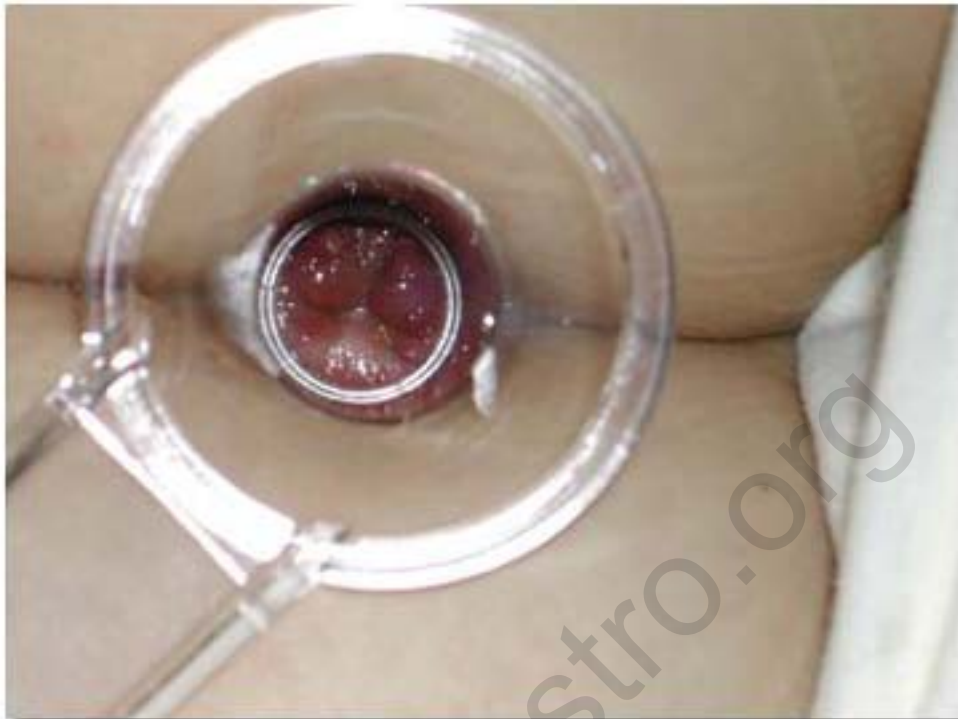


Clinical Quiz #3

A 14-year-old girl presents with recurrent mucous bloody stool. She has received mezlazine 1x3 , Lactobacilli 1x3 ,zinc sulfate 1x1 and mega dose of multivitamins. She still complains of frequent loose and slimy stool. Proctoscopic exam as shown.



What is your diagnosis and further treatment?

[Click for answers](#)

Contributed by Boosba Vivatvakin MD.King Chulalongkorn Memorial Hospital

Clinical Quiz #3

Diagnosis: Ulcerative colitis

Start Budesonide rectal enema 6 mg bid for 2 weeks then tapering off.

Pthaigastro.org