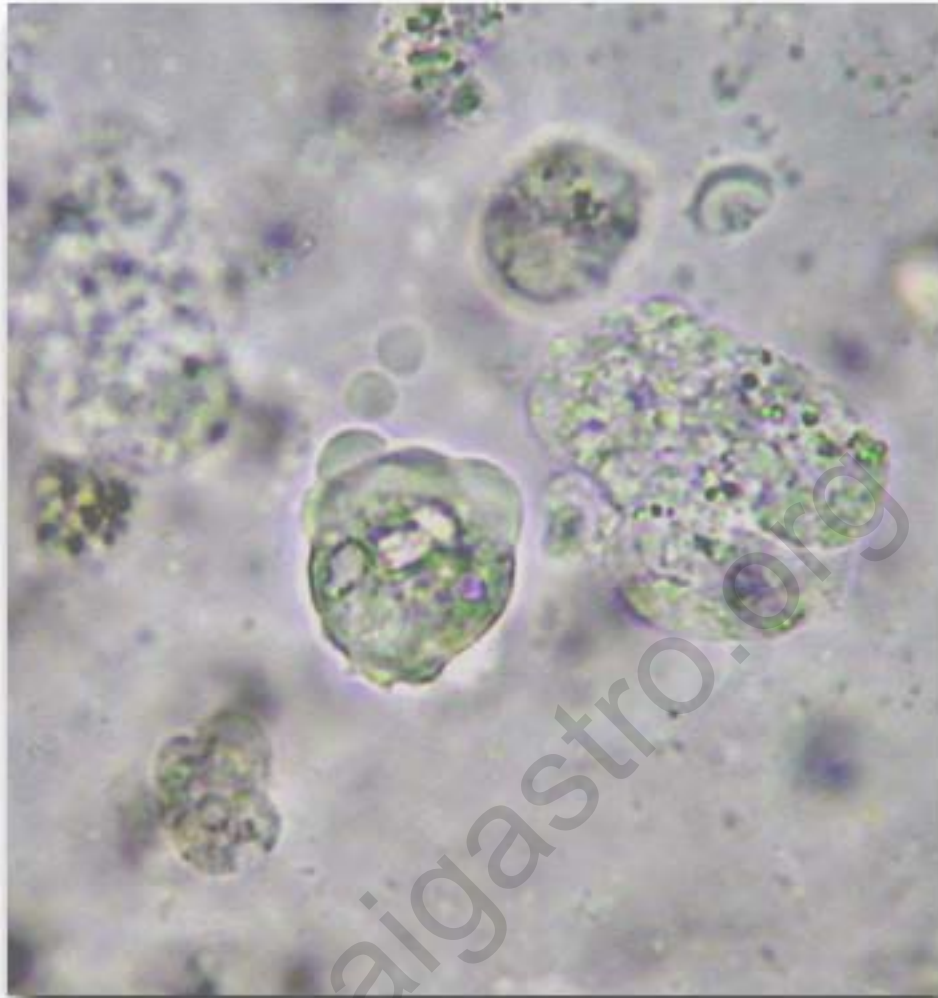


Clinical Quiz #6

A 6-year-old boy presents with fresh blood per rectum for 1 year. Stool examination reveal:



What is your diagnosis ?

[Click for answers](#)

Contributed by Nuthapong Ukarapol, MD. Chiang Mai University

Clinical Quiz #6

Diagnosis: Amebic trophozoite

The colonoscopy shows multiple shallow ulcers with colitis, predominantly at the recto-sigmoid region. The patient is treated with metronidazole 30 MKD for 10 days.

Pthaigastro.org