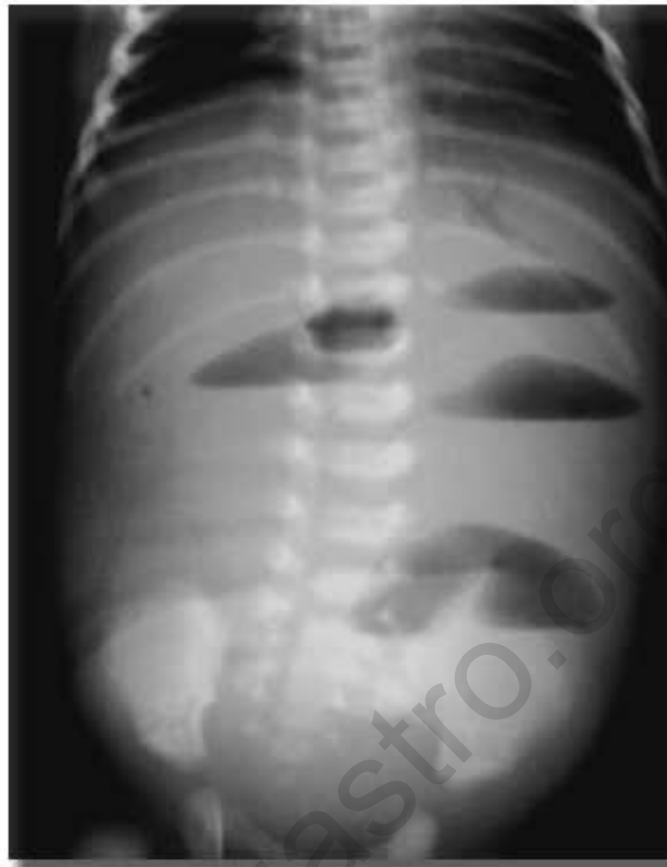


Clinical Quiz #7

A newborn infant presented with abdominal distention and vomiting.
The plain abdomen showed:



What is your diagnosis ?
[Click for answers](#)

Contributed by Nuthapong Ukarapol, MD. Chiang Mai University

Clinical Quiz #7

Diagnosis: Ileal atresia

The plain abdomen showed evidence of small bowel obstruction with multiple air-fluid levels.

Pthaigastro.org